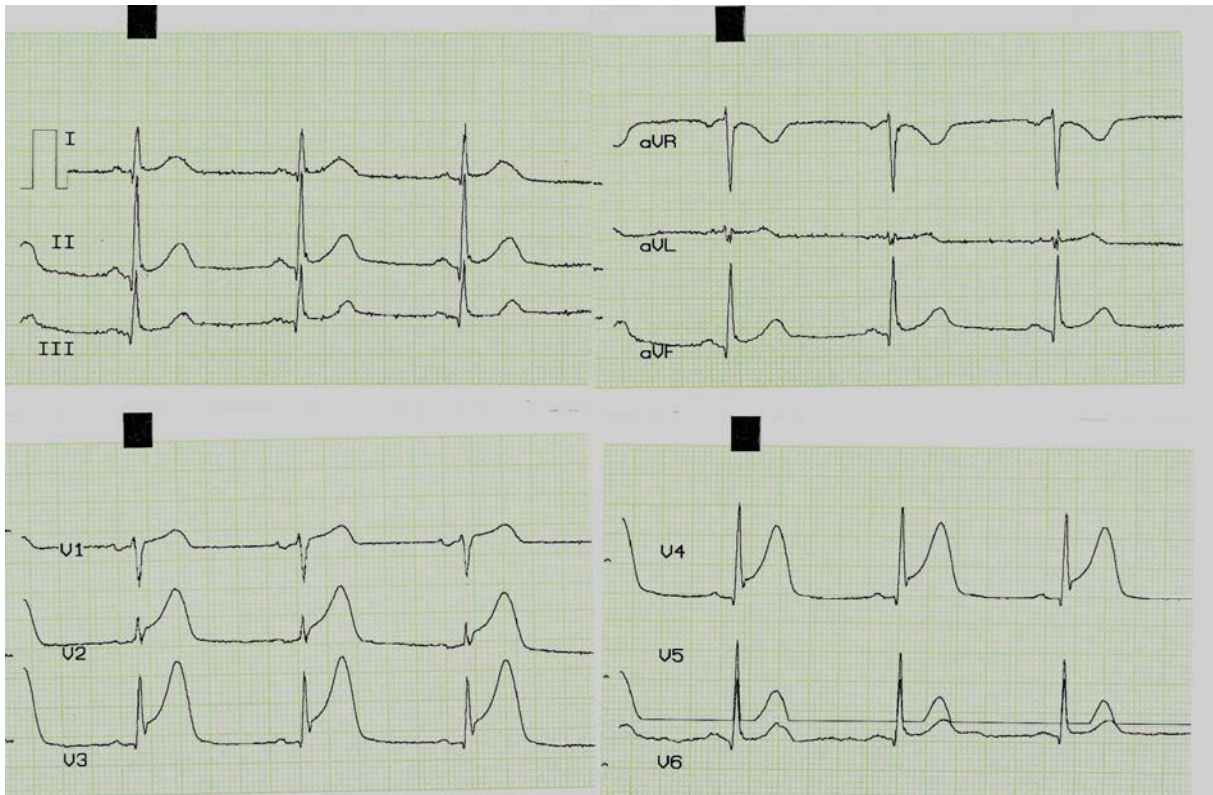
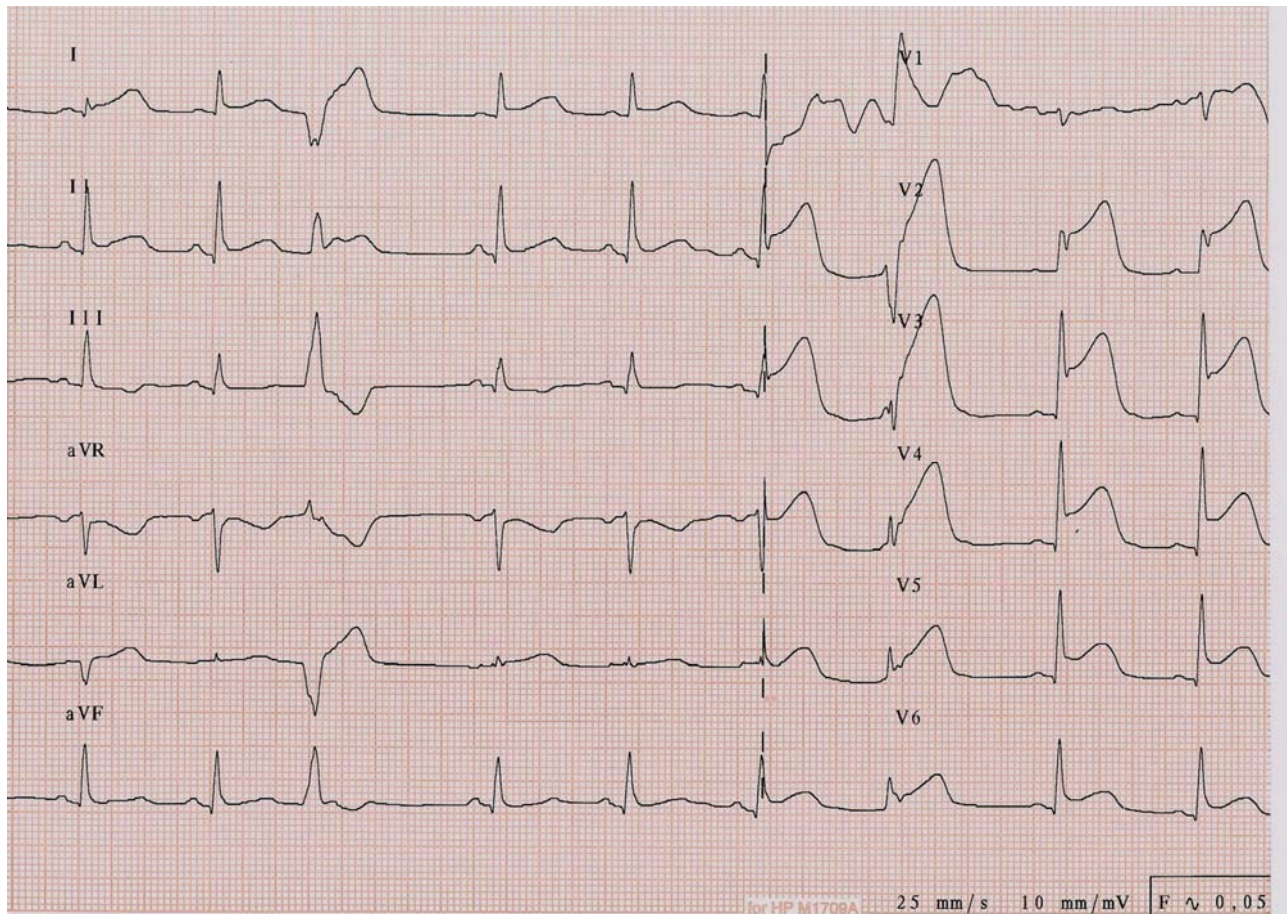


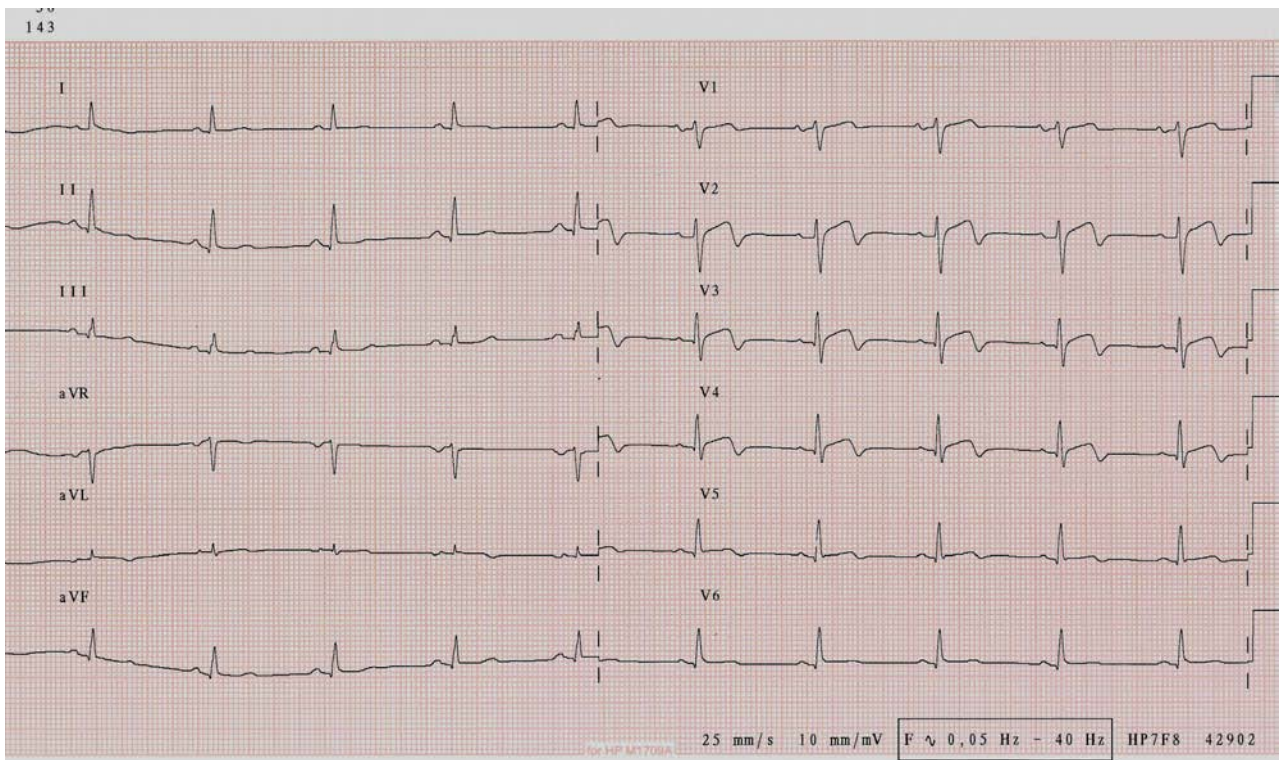
Douleur préc 21/03/04 à 11h16 SAMU



CHU 13h22

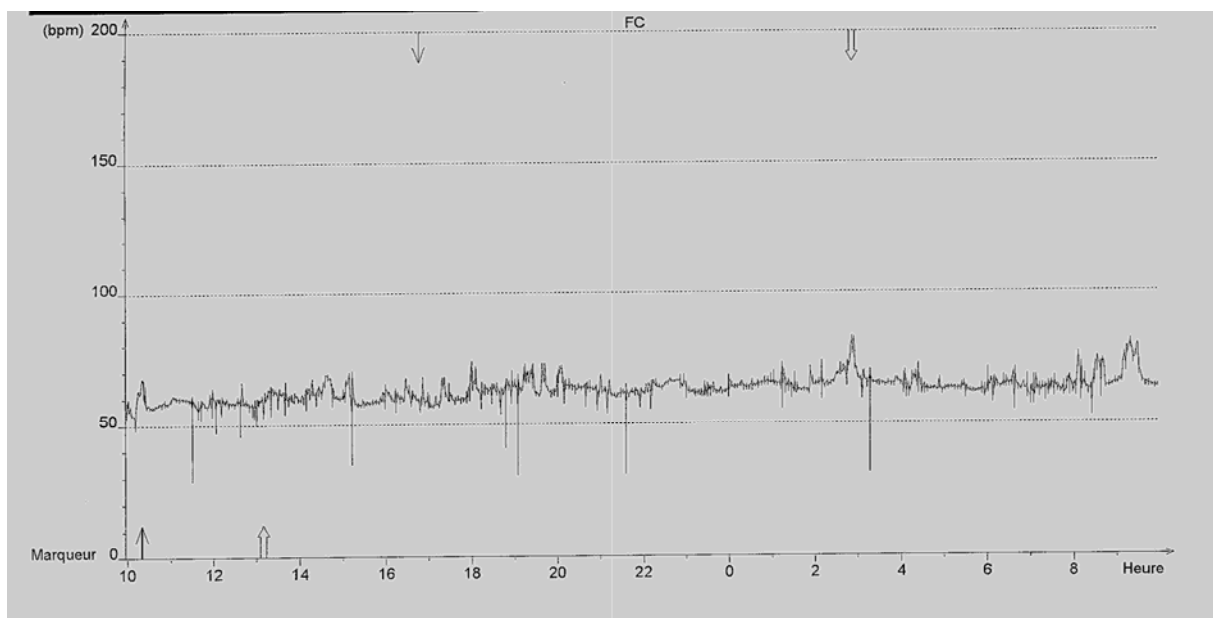


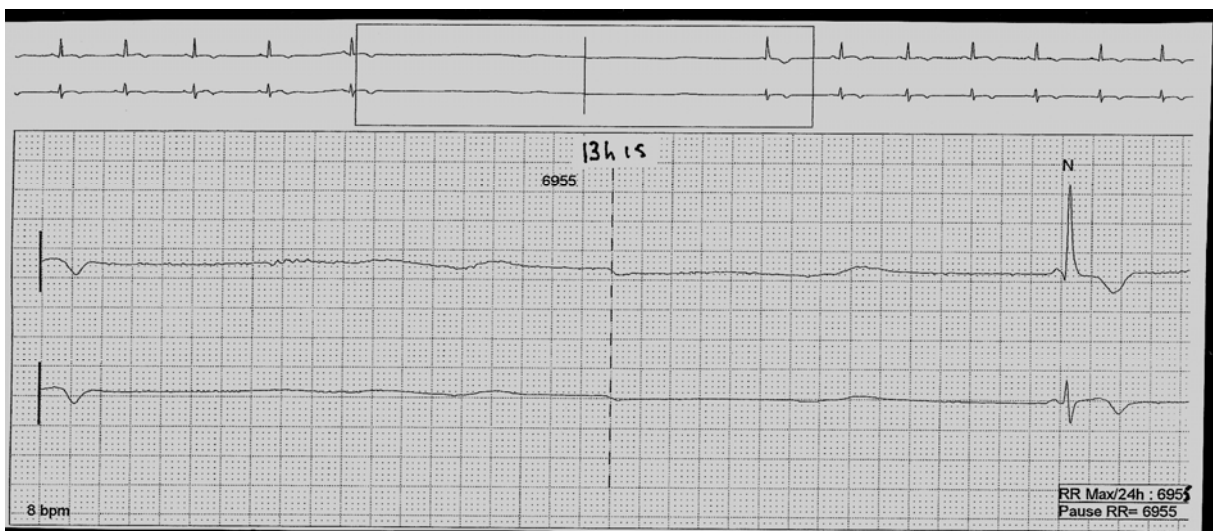
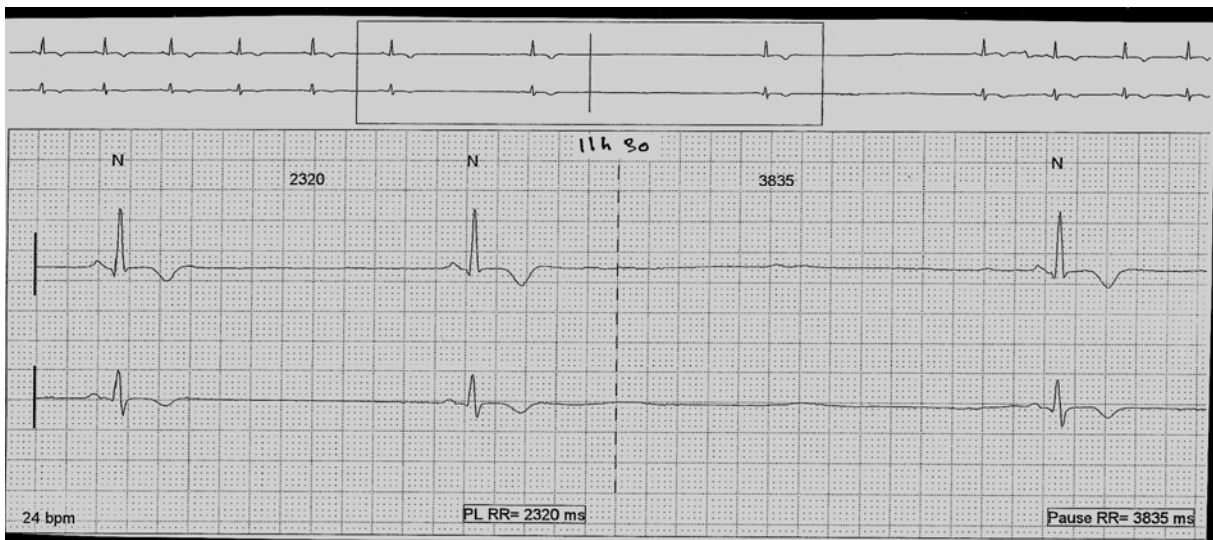
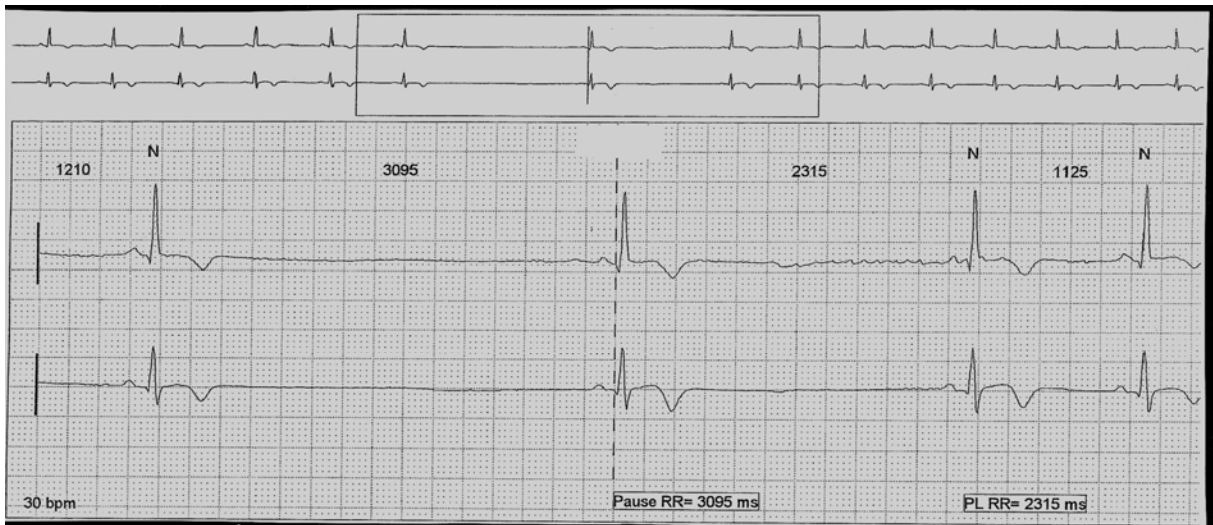
après ttmt

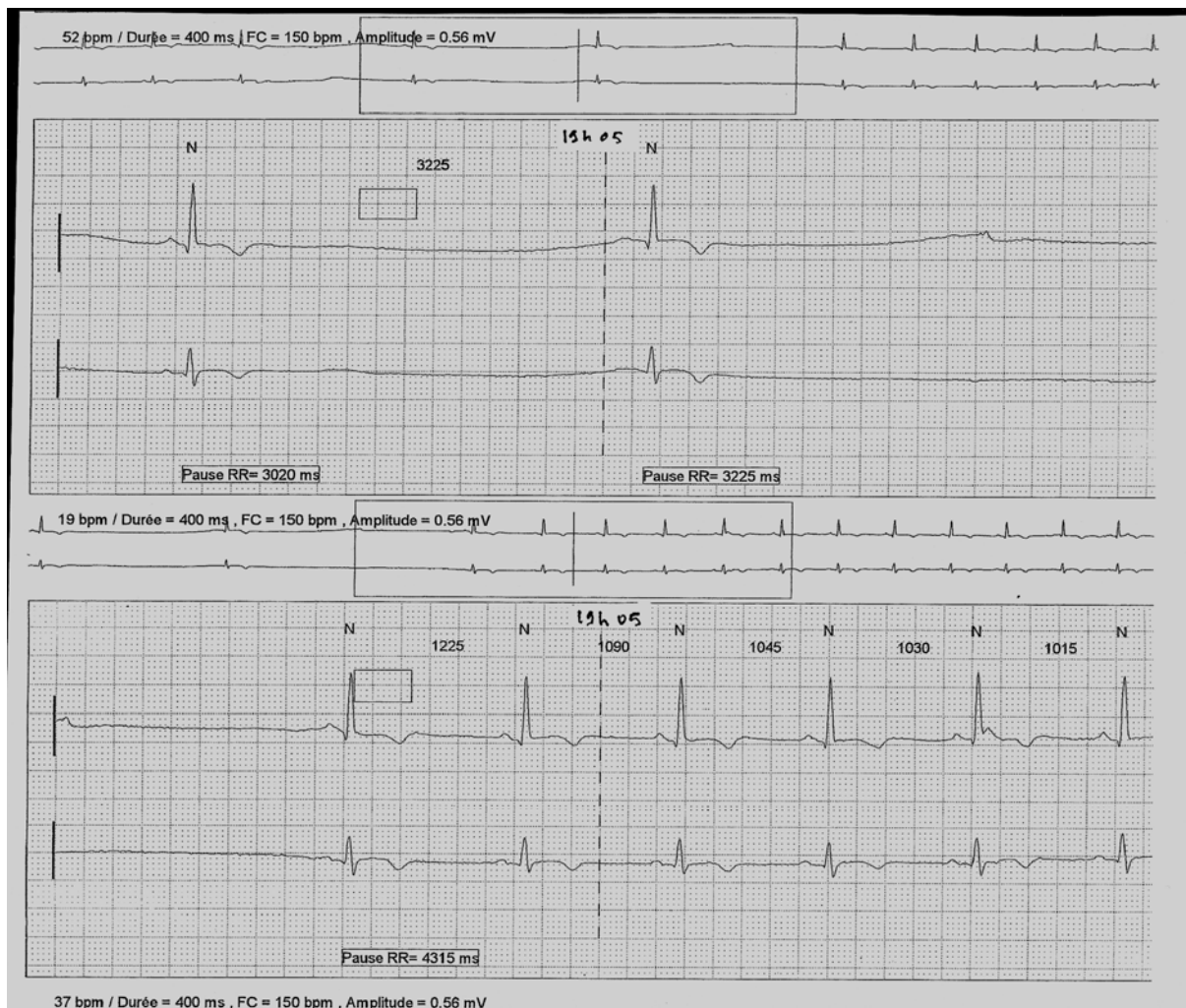


mise sous aténolol 50 mg ralentissement de la fréquence cardiaque et malaises

ECG de 24 h







Analysez les données de l'enregistrement ECG de 24 h

Quelles conclusions thérapeutiques